

# Non-scarring Minimal Incision Neo-omphaloplasty in Abdominoplasty: The Alvarez Technique. A New Proposal

Edwar Alvarez, MD\*  
David Alvarez, MD†  
Alberto Caldeira MD‡¶

**Background:** Abdominoplasties are increasingly requested aesthetic, reconstructive surgical procedures that, in most cases, have shown the disadvantage of leaving an often-notorious periumbilical scar due to hypertrophy, keloid, or because it simply remains very visible over time, after surgery. The Alvarez technique (or nonscarring minimal-incision neo-omphaloplasty) is a completely new, unprecedented technique because it does not leave visible scars. This technique requires the generation of four small flaps and a purse-string suture system interacting with the aponeurosis of the rectus abdominis muscles, as well as the modification of the vertical abdominal plication, and management of the subcutaneous cellular tissue in the new umbilicus area, which, if executed correctly, provide adequate aesthetic results.

**Methods:** A multicentric case-series scientific study is presented with a total of 94 patients who underwent classical abdominoplasties and neo-omphaloplasties with the aforementioned technique from August 2018 to December 2020. Pre-surgical and post-operative photographic files were collected.

**Results:** Of the 94 patients, there were eight (8.5%) cases of seroma, which are not attributable to neo-omphaloplasty but inherent to the use of drains. There were five (5.3%) cases of umbilical dehiscence. In total, 89.2% (84 patients) showed a very high degree of long-term satisfaction, and 10.6% (10 patients) had a medium level of long-term satisfaction.

**Conclusions:** The Alvarez technique provides good aesthetic results that are well accepted among patients and surgeons, in the short and long term. It is useful for those patients who wish to undergo an abdominoplasty but cannot stand a scar in the umbilical region. (*Plast Reconstr Surg Glob Open* 2021;9:e3956; doi: [10.1097/GOX.0000000000003956](https://doi.org/10.1097/GOX.0000000000003956); Published online 22 November 2021.)

## INTRODUCTION

The navel is the most important anatomical and aesthetic unit of the anterior abdominal wall. It is a scar itself, resulting from the detachment of the umbilical cord in the newborn, and it is physiologically located in the midline, 1 or 2 cm above a horizontal line that joins both iliac crests, about 18–20 cm above the beginning of the vulvar commissure. It may have a round or oval vertical shape.<sup>1,2</sup> During an abdominoplasty, it is important to carry out an adequate neo-omphaloplasty resulting in an anatomically preserved navel, with its mamelon, depressions, umbilical

groove and located in the right position, which means 13–14 cm above the horizontal abdominal scar<sup>2-4</sup>

## History of Neo-omphaloplasty

In the 1960s, doctors Gillies and Millard briefly described the omphaloplasty procedure in their book *The Principles and Art of Plastic Surgery*. However, one of the first recognized authors to discuss omphaloplasty as a complex and isolated procedure was Vernon, with his well-known technique based on a circular incision of the umbilical contour and subsequent reinsertion into the remaining abdominal flap.<sup>5</sup> In 1967, Ivo Pitanguy described his technique with a transverse or crescent-shaped incision without cutaneous resection.<sup>6,7</sup> In 1976, Juarez Avelar incised the umbilical scar, generating three resulting flaps that were sutured together with three others generated in the abdominal wall, a technique known as the Mercedes Benz cross or star pattern.<sup>8,9</sup> In 1978, Freeman and Wiemer described an inverted omega incision to obtain a flap in which, once a small segment of its free edge has been

From the \*Plastic Surgery service at Clínica Continental, Latacunga, Ecuador; †Instituto Avançado de Cirurgia Plástica – IACP/Hospital Casa Evangélico/UNIBAHIA, Rio de Janeiro, Brazil; ‡Department of Plastic Surgery at Instituto Avançado de Cirurgia Plástica – IACP/Hospital Casa Evangélico/UNIBAHIA, Rio de Janeiro, Brazil; and ¶Federal University of the State of Rio de Janeiro (UNIRIO), Rio de Janeiro, Brazil.

Received for publication September 13, 2021; accepted October 4, 2021.

Copyright © 2021 The Authors. Published by Wolters Kluwer Health, Inc. on behalf of The American Society of Plastic Surgeons. This is an open-access article distributed under the terms of the [Creative Commons Attribution-Non Commercial-No Derivatives License 4.0 \(CCBY-NC-ND\)](https://creativecommons.org/licenses/by-nc-nd/4.0/), where it is permissible to download and share the work provided it is properly cited. The work cannot be changed in any way or used commercially without permission from the journal.

DOI: [10.1097/GOX.0000000000003956](https://doi.org/10.1097/GOX.0000000000003956)

**Disclosure:** The authors have no financial interest to declare in relation to the content of this article.

Related Digital Media are available in the full-text version of the article on [www.PRSGlobalOpen.com](https://www.PRSGlobalOpen.com).

resected, it is fixed to the upper pole of the umbilical scar.<sup>10</sup> In 1979, Juri made a V-shaped incision in the abdominal wall to suture it to the umbilical scar, in the upper pole of which a V-shaped tissue segment is resected and fitted. In 1999, Cannistrá and Pecorelli designed a double “Y” mark to be attached to the incised umbilical edges resulting in a double “M” shape.<sup>10,11</sup> In 2006, Malic made an inverted U incision in the umbilical wall, for it to be sutured with a similar incision in the lower pole of the umbilical scar.<sup>11</sup>

In 2011, Furtado proposed his technique of an elongated figure eight to later suture the umbilical scar that was previously shaped like a diamond. This technique is known as the infinity technique.<sup>12</sup>

Before 2015, Hoyos performed his neo-omphaloplasty technique, consisting of four flaps, two major central flaps, and two minor lateral triangular flaps, where he performed a lipectomy below those flaps and a deep fixation to muscle fascia, with good results.

In 2015, Young Lee et al described the four X-shaped flaps technique, with their axes measuring more than 1 cm. In this technique the subcutaneous cellular tissue of said flaps is removed and a simple anchoring of each flap is performed toward the muscle fascia by means of simple stitches.<sup>13</sup>

In 2019, Reho published a technique where a vertical periumbilical 2 × 1 cm oval incision is made, together with deep anchorage of the navel to the muscle fascia and umbilical transposition. In this technique, the recipient bed is shaped like a “V,” and the fatty tissue is removed from the edge to release the dermis and allow umbilical anchorage. He performed this technique in 147 abdominoplasties.<sup>14</sup>

### Anatomy and Physiology: Umbilical Irrigation

The navel blood supply comes from the subdermal plexus, from three different sources. The main supply comes from tributary arterioles originating to the right and left of the deep inferior epigastric arteries that ascend between the rectus muscle and the rectus sheath on their way to the umbilicus. The additional flow comes from the round ligament and the median umbilical ligament, as well as the adipose pad that surrounds the umbilical stem.<sup>15</sup> Venous drainage flows upward to the thoracic epigastric and lateral thoracic veins and downward toward the great Saphenous vein. Subcutaneous veins located along the round ligament can generate porto cava anastomosis at this level.<sup>16</sup>

### Ideal Navel Positioning

Multiple classical authors have described the correct position of the navel in the midline, between the third and fourth lumbar vertebrae. However, in our opinion, this description lacks clinical precision and falls within the realm of subjectiveness. Likewise, other authors have tried to describe the correct position of the umbilical scar taking the umbilical pedicle, the waist, the sternum, the xiphoid appendix, the pubis and the iliac crests as reference points.<sup>17</sup> In the horizontal plane, anatomical texts and the first publications on abdominoplasty locate the umbilicus in the midline and at level of or on an imaginary line connecting both iliac crests.

### Takeaways

**Question:** Is there a surgical alternative in neo-omphaloplasty that avoids external scars and allows the umbilical roll to be reconstructed?

**Findings:** A multicentric case-series scientific study is presented with a total of 94 patients who underwent classical abdominoplasties and neo-omphaloplasties with the Alvarez technique from August 2018 to December 2020. Of the 94 patients, 89.2% (84 patients) showed a very high degree of long-term satisfaction, and 10.6% (10 patients) had a medium level of long-term satisfaction.

**Meaning:** Non-scarring minimal-incision neo-omphaloplasty is a new surgical technique to avoid scars in the navel area.

The findings of Rohrich et al suggest that the normal navel position, according 116 photographs of standardized female patients, in 114 of whom, the navel is located slightly lateral to the midline; concluding that it is more frequent for the navel to be located in a plane slightly to the right, then slightly to the left of the midline, and finally in the middle line.<sup>18</sup> This finding is important when evaluating the patient before surgery.

On the vertical plane, there has been more controversy. Vernon described the new navel position when performing a lipectomy, right on the midline at the level of both iliac crests.<sup>19</sup> Trying to achieve a more accurate description, Dubou<sup>20</sup> measured the umbilicus location in 100 non-obese subjects randomly selected and found that the navel transects, in 96% of subjects, in a line passing through a higher level of the iliac crests.

In our experience, we placed the ideal location of the navel 14 cm from the transverse abdominal scar—as recommended by Dr. Caldeira in his publications<sup>2,4</sup>—since, when performing the vertical abdominal plication, a natural descending effect of the umbilical stem is produced, which must be taken into account and corrected so as not to locate the future navel too close to the scar, providing the appearance of an elongated, stylized abdomen, which has been a constant issue for most of the described techniques.<sup>21,22</sup>

### Surgical Technique Description

Surgeons perform abdominoplasties by means of their preferred techniques, with the specificity that the original navel is completely removed together with the dermal-fat flap. We prefer to keep the dermal-fat flap anchored to facilitate traction and supraumbilical tunneling, and we remove it after performing the vertical plication (Fig. 1). (See Video 1 [online], which shows how the abdominoplasty can be performed with the preferred approach of each surgeon.)

We then remove the dermal-fat flap by cutting it at its base, on the umbilical stem. A 1 cm remnant of the umbilical stem is left. We repair the resulting defect with a 2/0 nonabsorbable Polyamide 6 suture (Dafilon) with X-shaped or inverted figure eight stitches (Fig. 2).

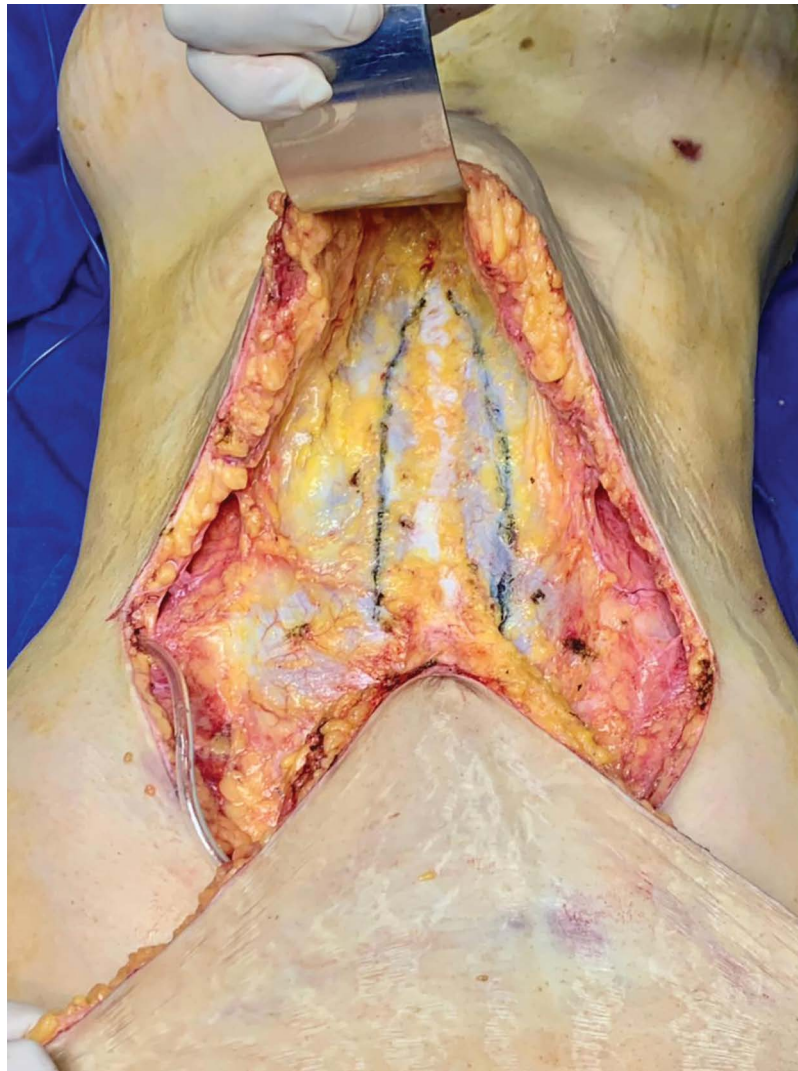
In the rectus abdominis muscles, we perform a vertical plication except for the place determined for the neo-navel, where we leave a 2 cm area without plication to be able to position the navel in this place (Fig. 3). (See Video 2 [online], which displays how the navel must be cut immediately below the dermis, leaving 1 cm of remaining umbilical stem.)

We pull the abdominal flap downward and fix it. Then, we mark the future umbilicus located 13–14 cm from the surgical approach. We mark the new navel's place on the skin by placing an N-18-gauge needle as a guide and checking its symmetry and correct location in the midline (Fig. 4). (See Video 3 [online], where we identify the ideal location of the new navel.)

Then we begin to work subcutaneously. Using the tip of the needle as a guide, we resect the subcutaneous cell tissue in a 2-cm-diameter circular area around the needle using Metzenbaum scissors and finally visualizing the free dermis (Fig. 5).

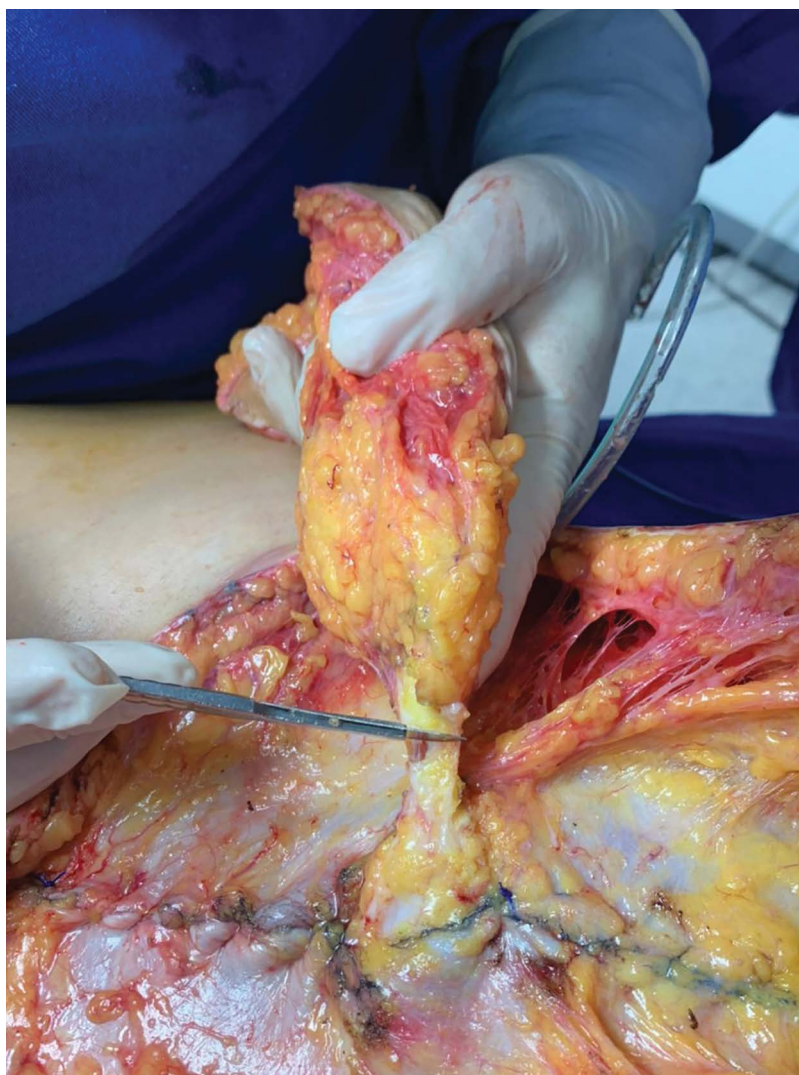We perform the first subcutaneous purse-string suture, using a 2/0 nonabsorbable Polyamide 6 suture (Dafilon) around the needle, in the area surrounding the free dermis area. This purse-string suture helps us generate the umbilical roll (Fig. 6). We remove the guide from the needle and make an X-shaped cut with an No 11 scalpel, with a 3 mm length in each axis; thus, obtaining four small flaps, one upper flap, one left flap, one lower flap, and one right flap. Then, we perform a second purse-string suture in the abdominal muscles, which will attach the umbilical stem the four dermal flaps, using a 2/0 nonabsorbable suture, and always following a clockwise pattern, as explained below.

At this time, it is important to be able to understand the new navel's shaping, and picture the remaining umbilical stem as a clock. Then, we begin suturing the muscle portion left without plication, and enter the umbilical stem at 6 o'clock. Afterward, we look for the first dermal flap on the left and take it with the suture. Then, we return to the



**Fig 1.** Detachment of the dermal-fat flap. The area of the future vertical muscle plication and the abdominal flap that will be removed can be seen. Source: intraoperative photographs of the author.





**Fig 2.** The definitive amputation of the umbilicus is carried out at the level of the stem, trying to leave a remnant of 1 cm. Source: intraoperative photographs of the author.

umbilical stem and enter at 3 o'clock. There, we take the upper flap and again go back to the umbilical stem and enter at 12 o'clock. Subsequently, we go toward the right flap and back to the umbilical stem around 9 o'clock. Next, we take the lower flap at its base to prevent possible tissue damage and return to the umbilical stem. Finally, the suture comes out through the muscle portion in front of where we started. (See Video 4 [online], which displays the reconstruction of the umbilical roll and development of the four mini skin flaps.)

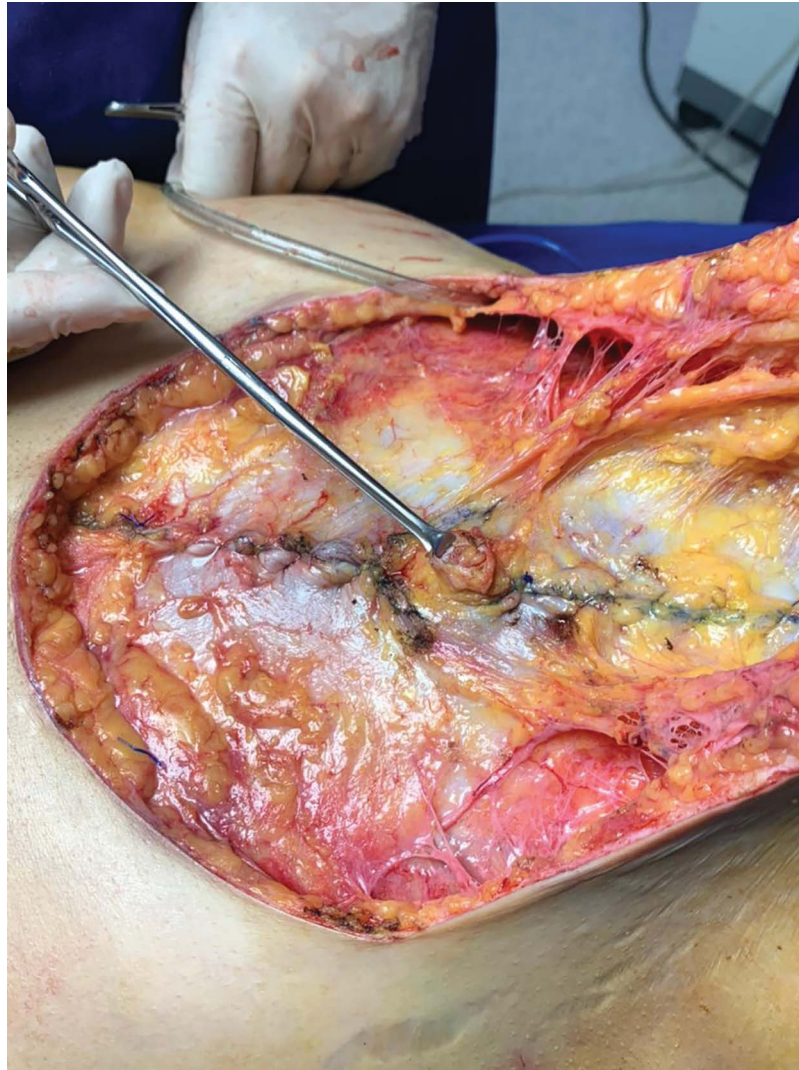
The free sliding of the suture thread is evident; thus, we tie it to complete the fixation of the new umbilicus and the pending muscle plication (Fig. 7).

Finally, we perform a simple lower anchorage of the dermis to the fascia with a single 2/0 nonabsorbable monofilament suture to shape our new scarless navel. Then we verify the symmetry, depth and anatomical characteristics, and close through the abdominoplasty anatomical planes. (See Video 5 [online], which shows the final anchoring of

the new navel.) (See Video 6 [online], which shows the final aesthetic appearance of the new navel.) We place suction drainage and recommend placing two alcohol swabs in the neo-navel as a complementary method for modeling maintenance.

## METHOD

A multicenter case series study with a total of 94 patients surgically intervened with the Alvarez technique for neomphaloplasty was analyzed by probabilistic sampling, including patients without comorbidities, who underwent surgery for lipoabdominoplasty, with grade III or IV abdominal deformity classification; at Clinica Continental SA in the city of Latacunga, province of Cotopaxi, Ecuador; in the period between September 2018 and August 2020 and its controls post, which completes the study up to December 2020. Once this time period concluded, the corresponding photographic archive was made, taking pictures immediately after surgery and then at 3 months



**Fig 3.** We perform vertical muscle plication in the classic way, with the modification of leaving an area of 2 cm around the remaining stem without plication. Source: intraoperative photographs of the author.

and at 6 months postoperative. Additionally, a qualitative evaluation survey questionnaire was distributed to both patients and surgeons who performed the technique. The SPSS 21.0 statistical program was used to tabulate the variables and obtain statistical results ([Table 1](#)).

## RESULTS

The age group with the highest number of patients operated on with this technique was between 41 and 50 years of age. There was a higher prevalence of type IV abdomen according to the abdominal deformity classification. Of the 94 operated patients, there were eight (8.5%) cases of seroma, which are not attributable to neo-omphaloplasty but rather inherent to the surgical procedure and the use or lack of use of drains. There were five (5.3%) cases of umbilical dehiscence; four (4.3%) cases of unsightly navels: two cases of skin pigmentation, one unnaturally looking navel, and one narrow-looking navel.

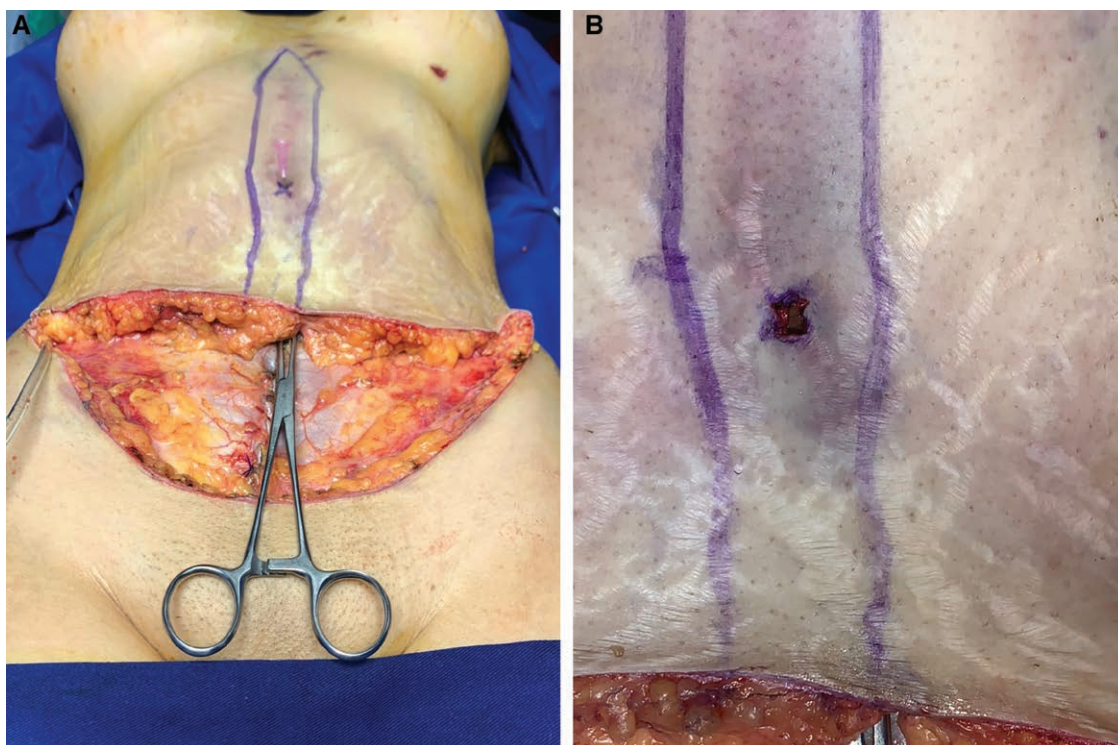
Of the 94 patients, 89.2% (84 patients) showed a very high degree of long-term satisfaction, and 10.6% (10 patients) had a medium level of long-term satisfaction, carried out through a satisfaction survey.

## DISCUSSION

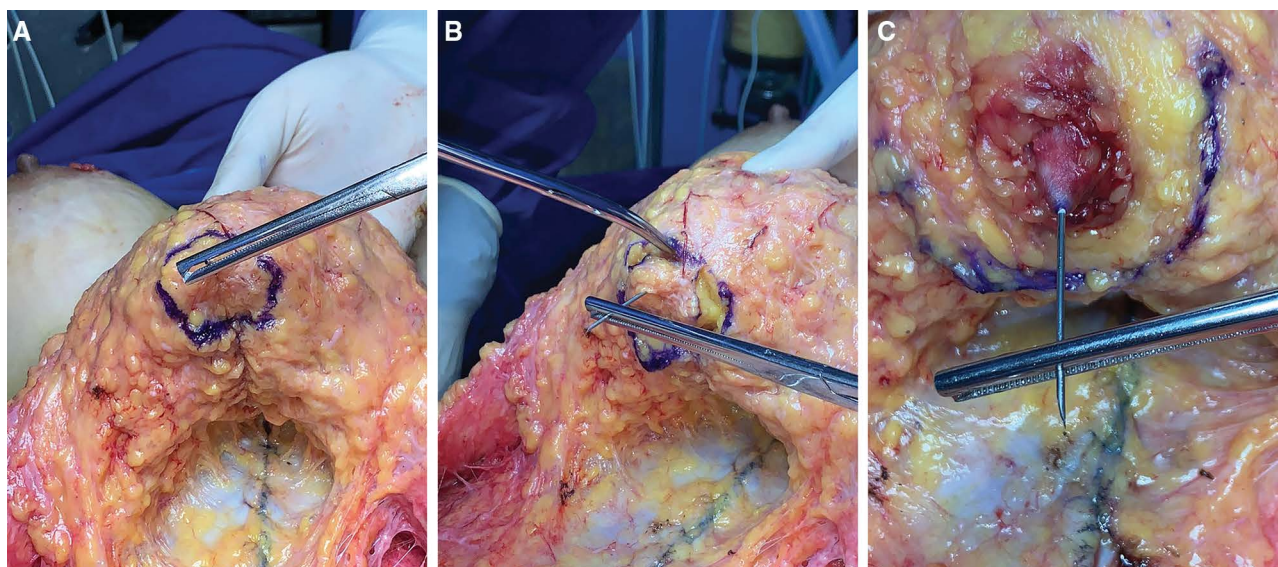
The Alvarez technique for neo-omphaloplasty is a new technique that offers interesting aesthetic results, thus providing an alternative for those patients who want to undergo the procedure, but who do not want to have visible scars in the umbilical area. The essence of this technique lies in its correct and precise design, which will give the new-navel a natural and aesthetic shape.

Abdominoplasty is one of the most requested surgeries in the field of plastic surgery because, currently, the body silhouette is a fundamental part of many aspects of daily life, mainly of women. They feel more accepted, with a

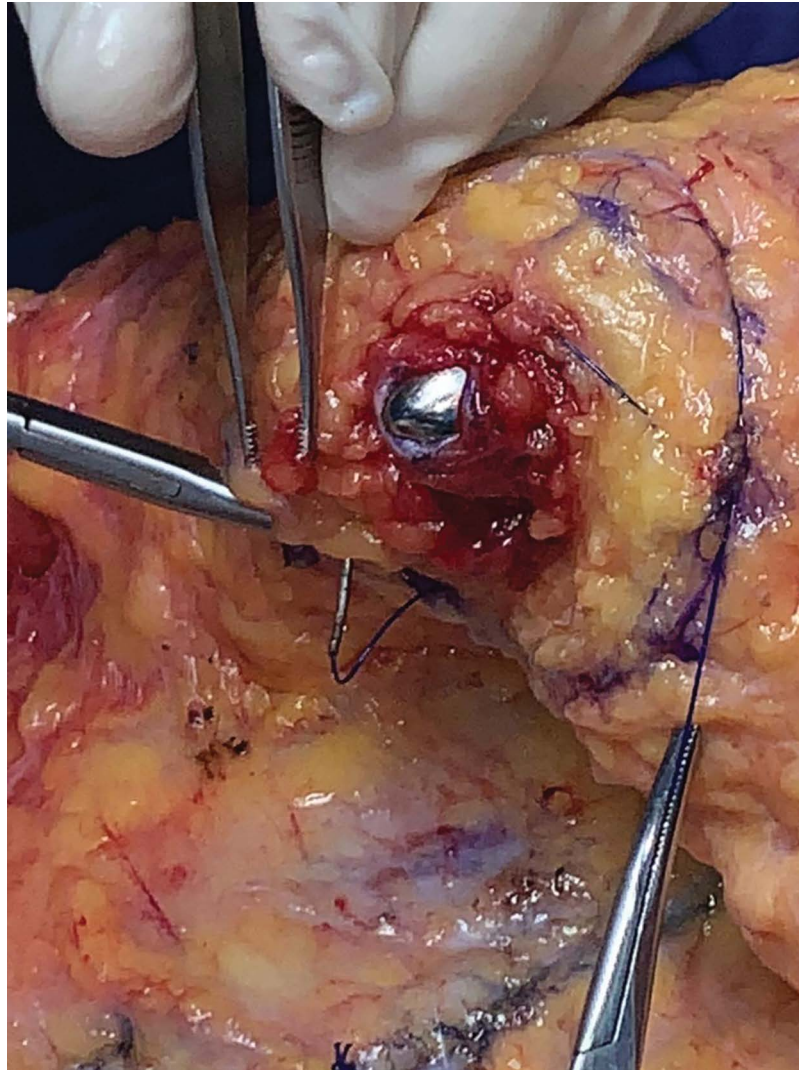




**Fig 4.** Key steps in non-scarring minimal incision neo-omphaloplasty. A, With the help of an N-18-gauge needle, we located the area of our new navel, located 14 cm from the future horizontal abdominal scar. After verifying symmetry, we proceed to create the four triangular flaps in the shape of an "X." B, Final appearance of the umbilical dermal flaps. Source: intraoperative photographs of the author.



**Fig 5.** Key steps in non-scarring minimal incision neo-omphaloplasty. A, From the subcutaneous aspect, we mark an area of 2 cm in diameter around the needle guide. B, We proceed to remove the fatty tissue in the marked area with the help of Metzenbaum scissors. C, Visualization of the dermis, cleansed of fatty tissue. Source: intraoperative photographs of the author.



**Fig 6.** We perform the first purse-string suture in the remaining fatty tissue area to make the internal umbilical rim. Source: intraoperative photographs of the author.

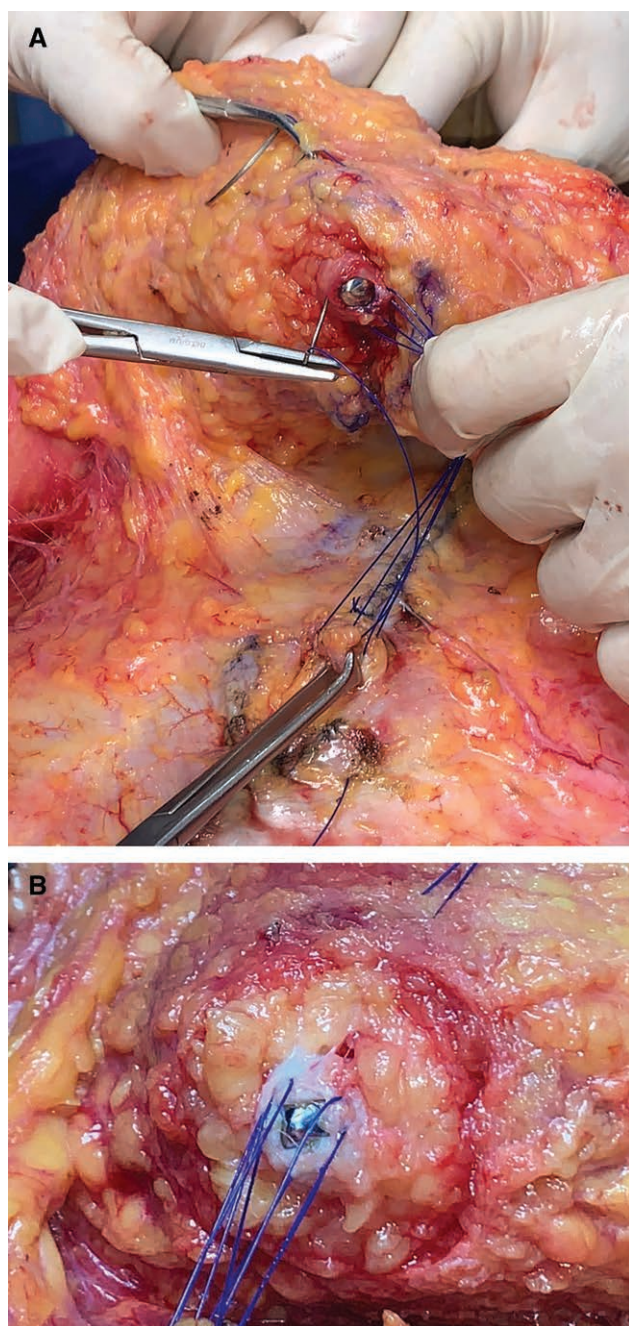
better quality of life and greater self-esteem. Nevertheless, we have heard many times in the consultation about the fear of the new navel's aesthetic result because it represents the most important anatomical unit of the anterior abdominal wall and it is also a symbol of beauty; thus, the presence of scars in it is unacceptable.

There have been many authors who have contributed with different neo-omphaloplasty techniques, within which umbilical transpositions, varied external approach designs, and deep dermal anchors have been described; yet many of them do not last in time or simply end up with an unnatural and unsightly result. However, all of them have provided us with valuable information to develop our technique. At the beginning of neo-omphaloplasty, Vernon's oval navels were a tendency to try to preserve the navel's shape, but this could result in stenosed navels or visible scars, so more and more authors have made different refinements in their techniques to

propose them in the medical literature, and as we can read in all their publications, have always tried to preserve the anatomical features described in the navel.<sup>23,24</sup> We have developed this new omphaloplasty technique as a new surgical alternative (independent from the abdominoplasty technique preferred by surgeons) which provides good, long-lasting aesthetic results. The Alvarez technique for neo-omphaloplasty does not increase the surgical time significantly, does not pose difficult management complications, and provides satisfactory results in patients.

At the beginning of using the Alvarez technique in 2018, the most frequent complication was umbilical dehiscence because in an attempt to achieve greater umbilical depth, the area in which the subcutaneous tissue was removed was wider and, therefore, less vascularized. Nowadays, we have standardized the subcutaneous cell tissue resection area to only 2 cm, which preserves vascular safety, preventing this dehiscence from happening again.





**Fig 7.** A, Correspondence between the dermis flaps and the umbilical stem. It is important not to cross the threads and allow them to slide freely. B, Dermal flaps must be taken at the base to avoid suffering from vertices. Total fixation of the four flaps to the umbilical stem. Source: intraoperative photographs of the author.

To avoid other possible complications such as umbilical stenosis and poor aesthetic appearance, it is very important to perform a proper reconstruction of the umbilical roll, which is described step-by-step in this article. In our experience, it is a fundamental step in creating the new navel and its aesthetic final appearance. Finally, two cases operated on with the technique showed pigmentation of the new navel after sun exposure, which was directly inherent to the postoperative care that was not properly complied with by the patient. Several authors have unsuccessfully tried to simply anchor the dermis to the abdominal fascia as if it were a Baroudi suture,<sup>25,26</sup> achieving poor results, without natural appearance and flattening over time. The Alvarez technique has a series of purse-string sutures, which cause the deep anchoring of four flaps and last over time. This provides the anatomical features that the navel must have, with the difference of being anchored and fixed to the deep planes. Some current photographic records of patients operated on with this technique are shown in Figs. 8–13.

## CONCLUSIONS

The Alvarez technique shows good aesthetic results in the short and long term, with limited minor complications that depend on the meticulous execution of the technique. It eliminates classic neo-omphaloplasty scar stigmas in the umbilical region without extending the surgical time more than 15 minutes and providing the patient with a new surgical non-scarring alternative with an aesthetic and pleasant result. It is useful for those patients who wish to undergo an abdominoplasty, but cannot stand a scar in the umbilical region, or for those patients who do not like the appearance of their natural navel.

**David Alvarez, MD**

Remigio Romero Cordero ave. and Angel Medardo Silva st.  
S / N, Clinica Continental, Rumipamba Neighborhood  
C.P. 050101, Latacunga  
Cotopaxi, Ecuador  
E-mail: [dr.davidalvarez@hotmail.com](mailto:dr.davidalvarez@hotmail.com)

## ACKNOWLEDGMENTS

*All procedures performed during this study with human participants were in accordance with the ethical standards of the institutional and national research committee and with the 1964 Declaration of Helsinki and its subsequent amendments or comparable ethical standards.*

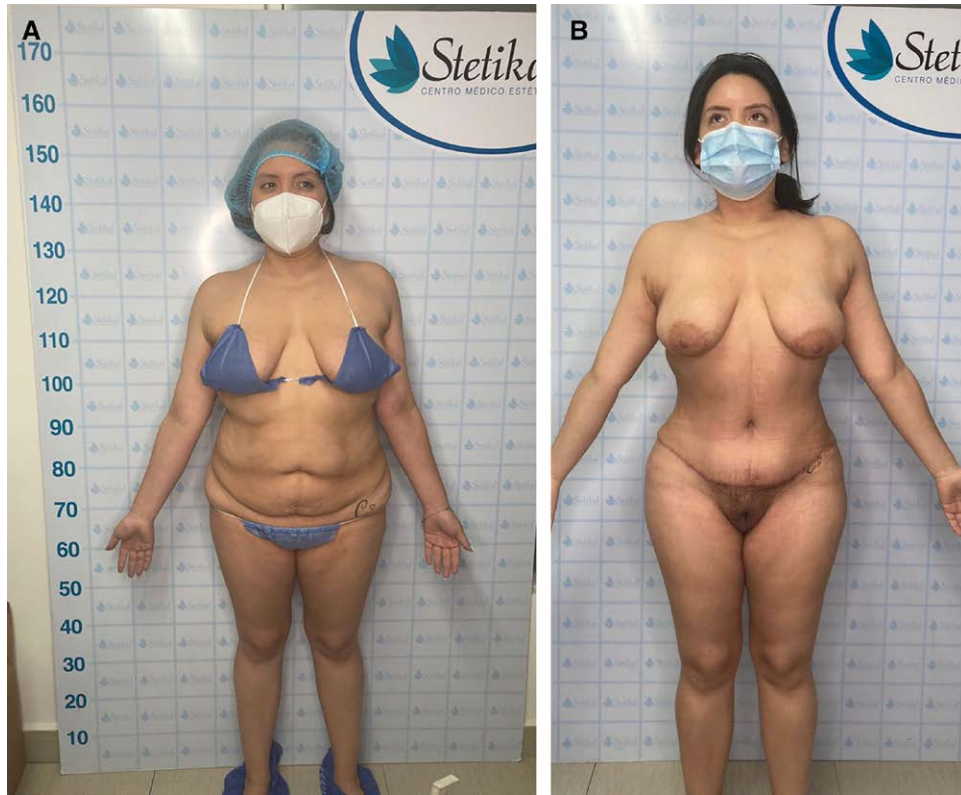## PATIENT CONSENT

*The patients provided written consent for the use of their images.*

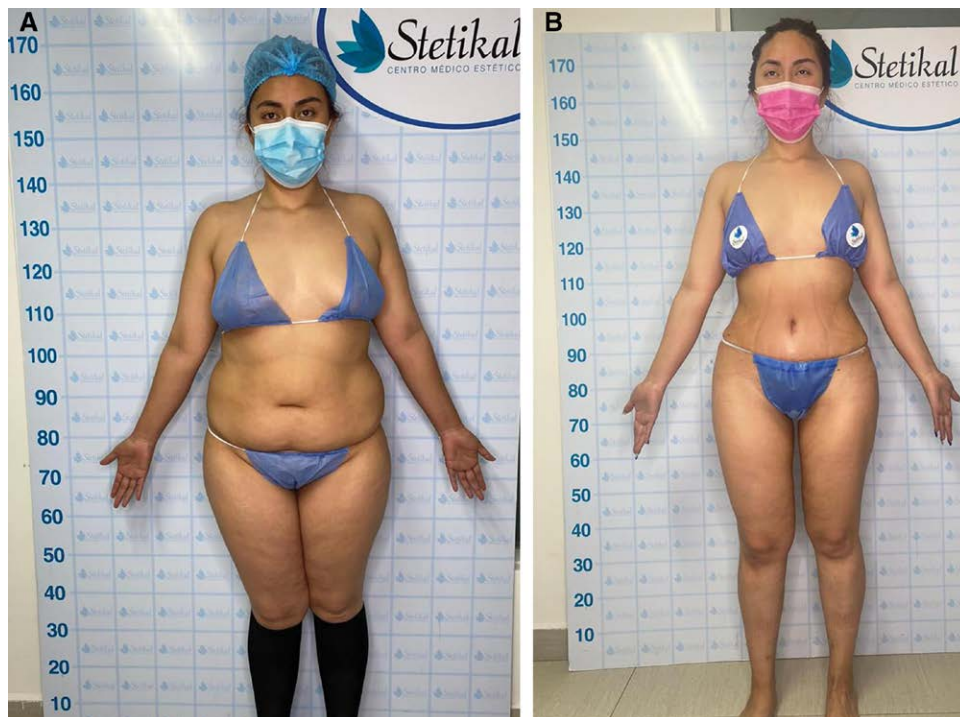**Table 1. Characteristics of the Patients Included in this Study**

Women	Men	28–35 Age Group	36–45 Age Group	>46 Age Group	BMI 28–34.9	BMI 35–39.9	BMI > 40	Nonsmokers	Smokers
92	2	14	21	57	17	28	47	85	7

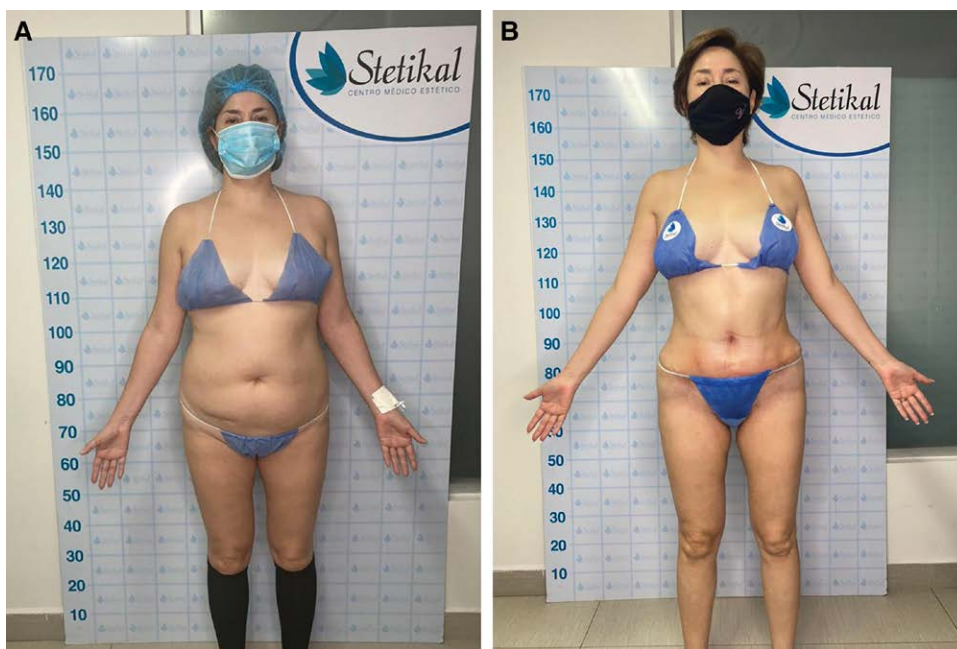



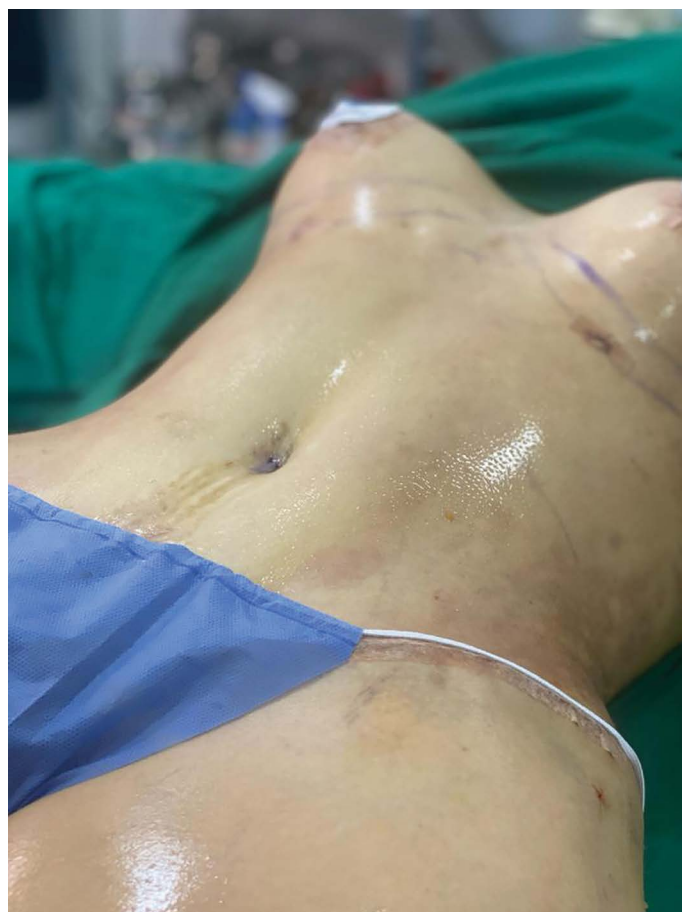**Fig 8.** A, Case 1. 40-year-old patient, grade IV abdominal deformities classification. BMI 32.3. Total amount of lipoaspirate: 5200 ml. B, Photograph taken 6 weeks after surgery. Liposculpture plus classical abdominoplasty and Alvarez technique neo-omphaloplasty were performed.



**Fig 9.** A, Case 2. 34-year-old patient, grade IV abdominal deformities classification. BMI: 31.7. Total amount of Lipoaspirate: 4800 ml. B, Photograph taken 3 months after surgery. Liposculpture plus classical abdominoplasty and Alvarez technique neo-omphaloplasty were performed. The stylized and elongated umbilical appearance is evident.

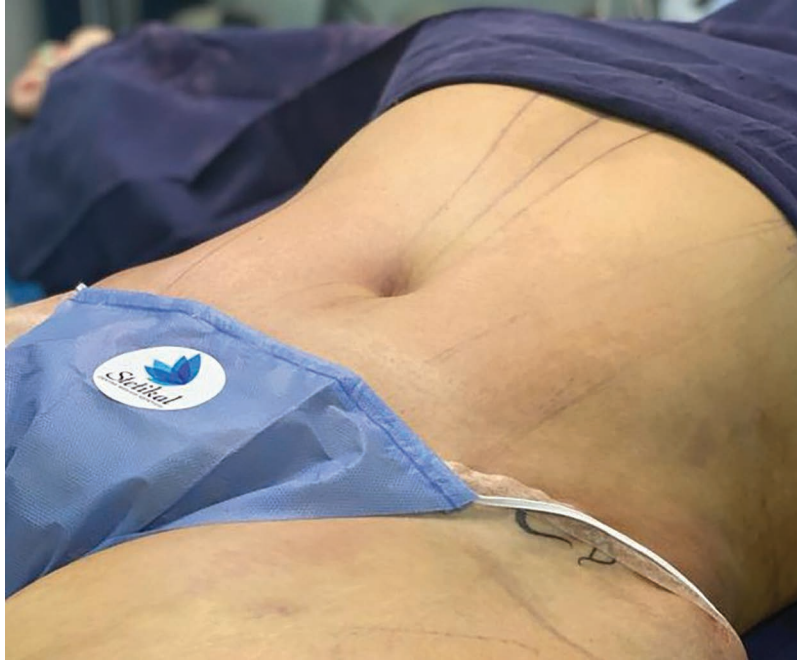

**Fig 10.** A, Case 3. 44-year-old patient, classification of grade III abdominal deformities at expense of adipose tissue. BMI: 30.6. Total amount of lipoaspirate: 3650 ml. B, Photograph taken 10 weeks after surgery. Lipoabdominoplasty and Alvarez technique neo-omphaloplasty were performed.

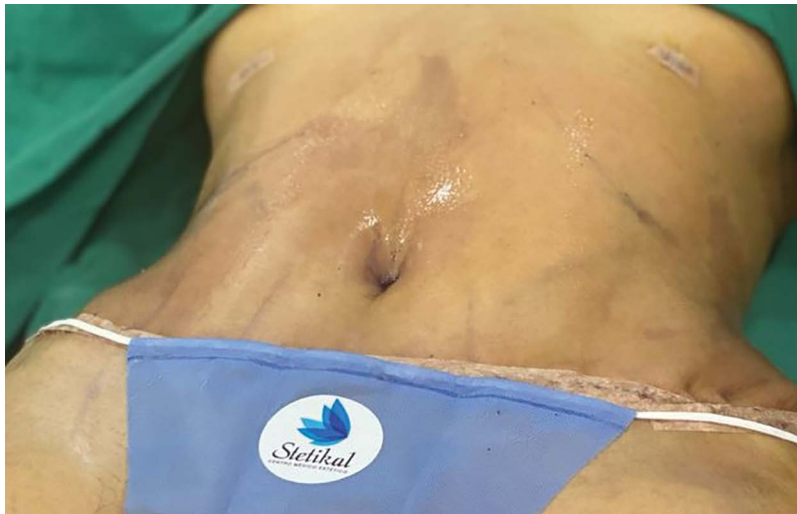

**Fig 11.** Case 8. Final aesthetic appearance of neo-omphaloplasty. Source: intraoperative photographs of the author.





**Fig 12.** Case 9. Aesthetic appearance of neo-omphaloplasty in the immediate postoperative period. Source: intraoperative photographs of the author.



**Fig 13.** Case 10. Final aesthetic appearance of neo-omphaloplasty. Adequate conformation of the umbilical rim and depth of the neo-umbilicus can be seen. Source: intraoperative photographs of the author.

#### REFERENCES

1. Kube-León R, Zapata R. Cirugía Plástica del contorno corporal. *Amolca, Lipoescultura, Abdominoplastia, Braquioplastia, Onfaloplastia, Gluteoplastia*. 2016;18:365.
2. Caldeira AML, Carrión K, Jaulis J. Focus on the importance of lipomid-abdominoplasty in the body contouring surgery. *Aesthetic Plast Surg*. 2019;43:718–725.
3. Sadler TW, Feldkamp ML. The embryology of body wall closure: relevance to gastroschisis and other ventral body wall defects. *Am J Med Genet C Semin Med Genet*. 2008;148C:180–185.
4. Caldeira AML, Nieves AP, Lima AO. Cirurgia do Contorno Corporal – Reflexões sobre um novo enfoque da cirurgia plástica do abdome. 1ª Parte – Classificações das deformidades abdominais e suas correlações cirúrgicas. *Rev Bras Cir*. 1990;80:95–104.
5. Langman J, Sadler TW. *Langman's Medical Embryology*. Philadelphia: Lippincott Williams & Wilkins; 1985:432.
6. Moore KL, Dalley AF, Agur AMR. *Clinically Oriented Anatomy*. Philadelphia: Lippincott Williams & Wilkins; 2014:1171.
7. Rohrich RJ, Sorokin ES, Brown SA, et al. Is the umbilicus truly midline? Clinical and medicolegal implications. *Plast Reconstr Surg*. 2003;112:259–263.

8. Dubou R, Ousterhout DK. Placement of the umbilicus in an abdominoplasty. *Plast Reconstr Surg*. 1978;61:291–293.
9. Abhyankar SV, Rajguru AG, Patil PA. Anatomical localization of the umbilicus: an Indian study. *Plast Reconstr Surg*. 2006;117:1153–1157.
10. Danilla S, Bonasic S. Anatomical localization of the umbilicus: a statistical analysis. *Plast Reconstr Surg*. 2007;119:1123–1124.
11. Craig SB, Faller MS, Puckett CL. In search of the ideal female umbilicus. *Plast Reconstr Surg*. 2000;105:389–392.
12. Mazzocchi M, Trignano E, Armenti AF, et al. Long-term results of a versatile technique for umbilicoplasty in abdominoplasty. *Aesthetic Plast Surg*. 2011;35:456–462.
13. Reho A, Randisi F, Ferrario A, et al. Scarless reverse umbilicoplasty: a new technique of umbilical transposition in abdominoplasty. *Plast Reconstr Aesthet Surg*. 2019;72:656–661.
14. Lee YT, Kwon C, Rhee SC, et al. Four flaps technique for neoumbilicoplasty. *Arch Plast Surg*. 2015;42:351–355.
15. Hoyos AE, Perez ME, Castillo L. Dynamic definition mini-lipoabdominoplasty combining multilayer liposculpture, fat grafting, and muscular plication. *Aesthet Surg J*. 2013;33:545–560.
16. Malic CC, Spyrou GE, Hough M, et al. Patient satisfaction with two different methods of umbilicoplasty. *Plast Reconstr Surg*. 2007;119:357–361.
17. Bruekers SE, van der Lei B, Tan TL, et al. “Scarless” umbilicoplasty: a new umbilicoplasty technique and a review of the English language literature. *Ann Plast Surg*. 2009;63:15–20.
18. Gillies H, Millard R, eds. *The Principles and Art of the Plastic Surgery*. Vol. 7. Boston: Little, Brown and Company; 1957:12.
19. VERNON S. Umbilical transplantation upward and abdominal contouring in lipectomy. *Am J Surg*. 1957;94:490–492.
20. Seung-Jun O, Thaller SR. Refinements in abdominoplasty. *Clin Plast Surg*. 2002;29:95–109, vi.
21. Pitanguy I, Salgado F, Murakami R, et al. Abdominoplastia. *Rev Bras Cir Clasificación de Técnicas Quirúrgicas*. 1955;85:23.
22. Avelar JM. *Umbilicoplastia*. Anais do 13 Congresso brasileiro de Cirurgia Plástica. Porto Alegre: Uma técnica sem cirurgia externa; 1976.
23. Avelar J. Abdominoplasty-Systematization of a technique without external umbilical scar. *Aesthetic Plast Surg*. 1978;2:141–151.
24. Freeman BS, Wiemer DR. Abdominoplasty with special attention to construction of the umbilicus: technique and complications. *Aesthetic Plast Surg*. 1978;2:65–74.
25. Juri J, Juri C, Raiden G. Reconstruction of the umbilicus in abdominoplasty. *Plast Reconstr Surg*. 1979;63:580–582.
26. Cannistrà C, Pecorelli E. Umbilical restoration in abdominal dermolipectomy: a simple double-Y, double-M technique. *Aesthetic Plast Surg*. 1999;23:364–366.